

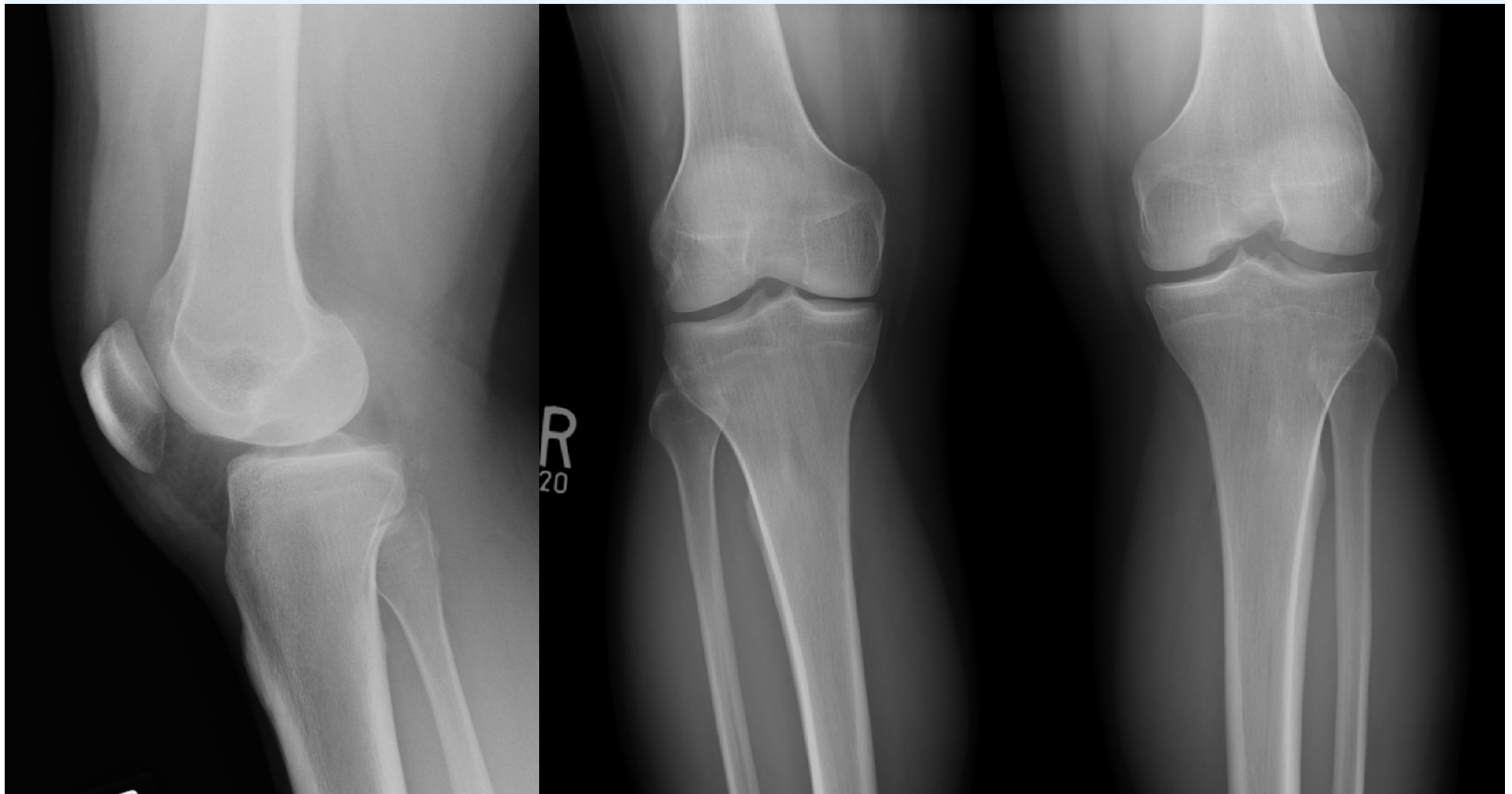


Patient Description

- Age: 28 yo
- Gender: Male
- Date of knee injury: Oct 2007
- Symptoms: Medial JL pain, locking
- Previous surgery: Arthroscopy, OCD fixation with resorb. Pins '01
- Co-morbidities:
 - Ligaments: normal
 - Alignment: neutral
 - Meniscus: normal
- Employment & activities of relevance:
Verizon field tech
- Patient expectations:
Return to work

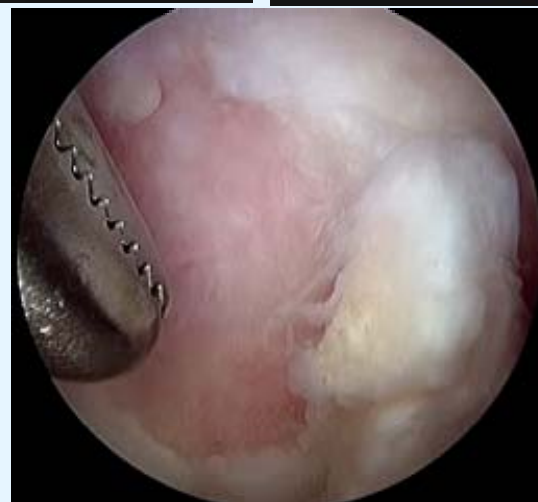
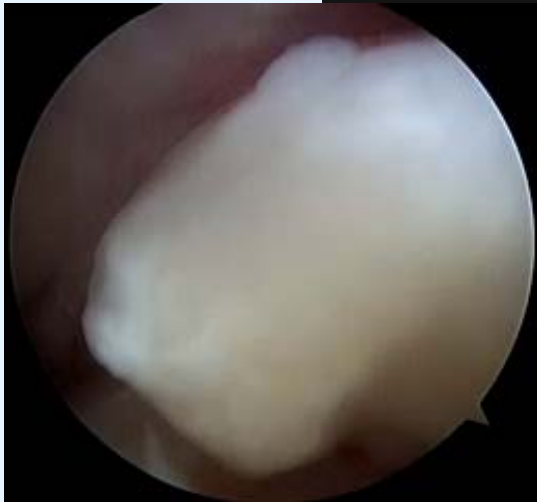
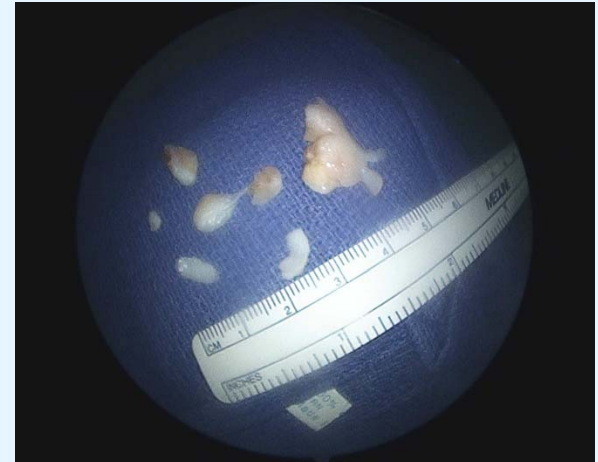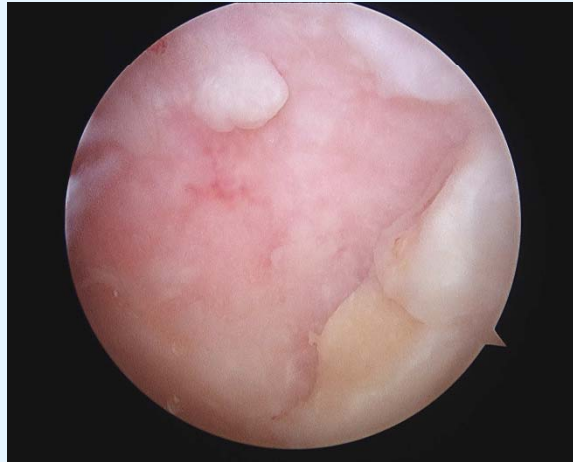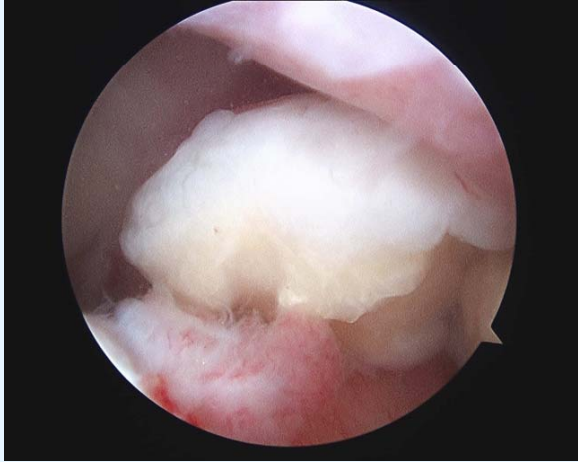Imaging





Arthroscopy

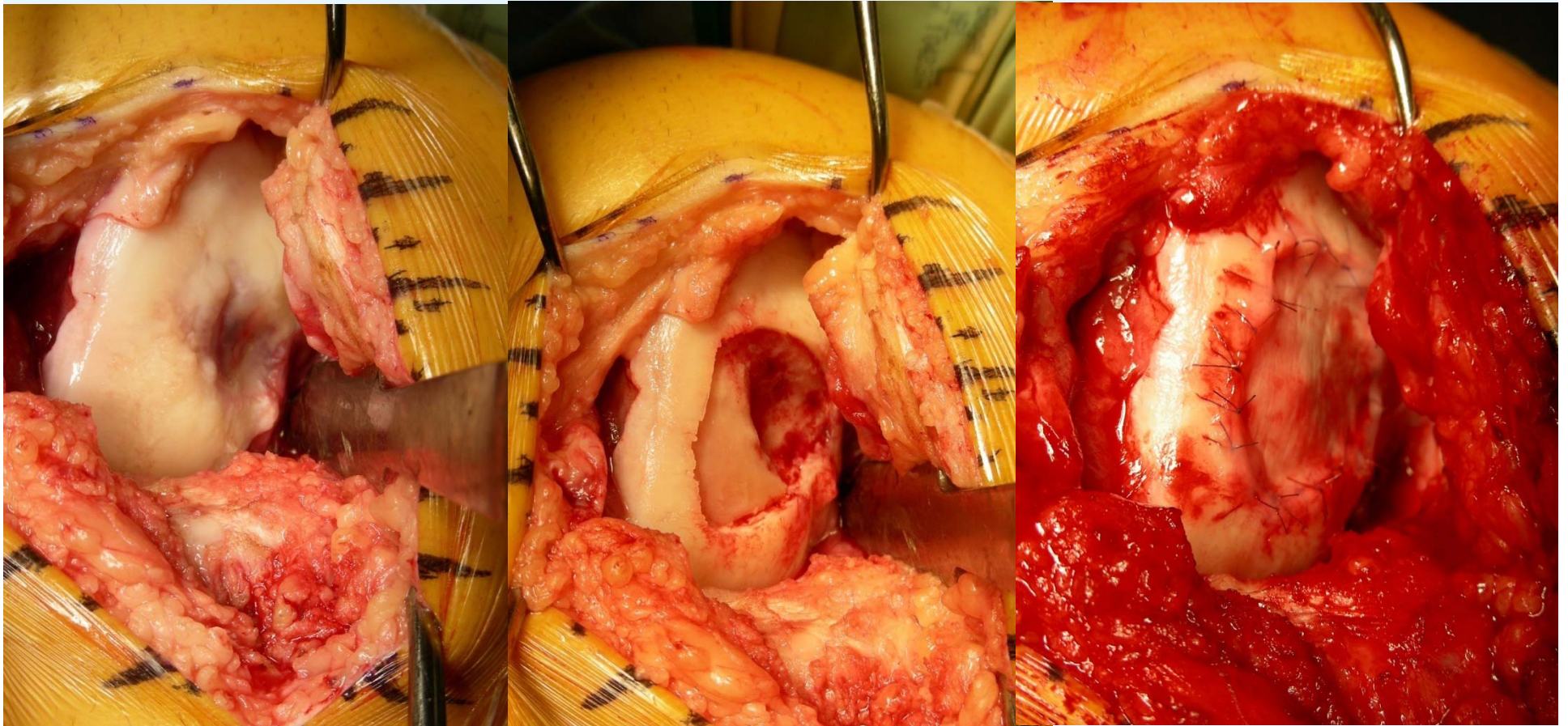




Cartilage Repair Center



ACI MFC

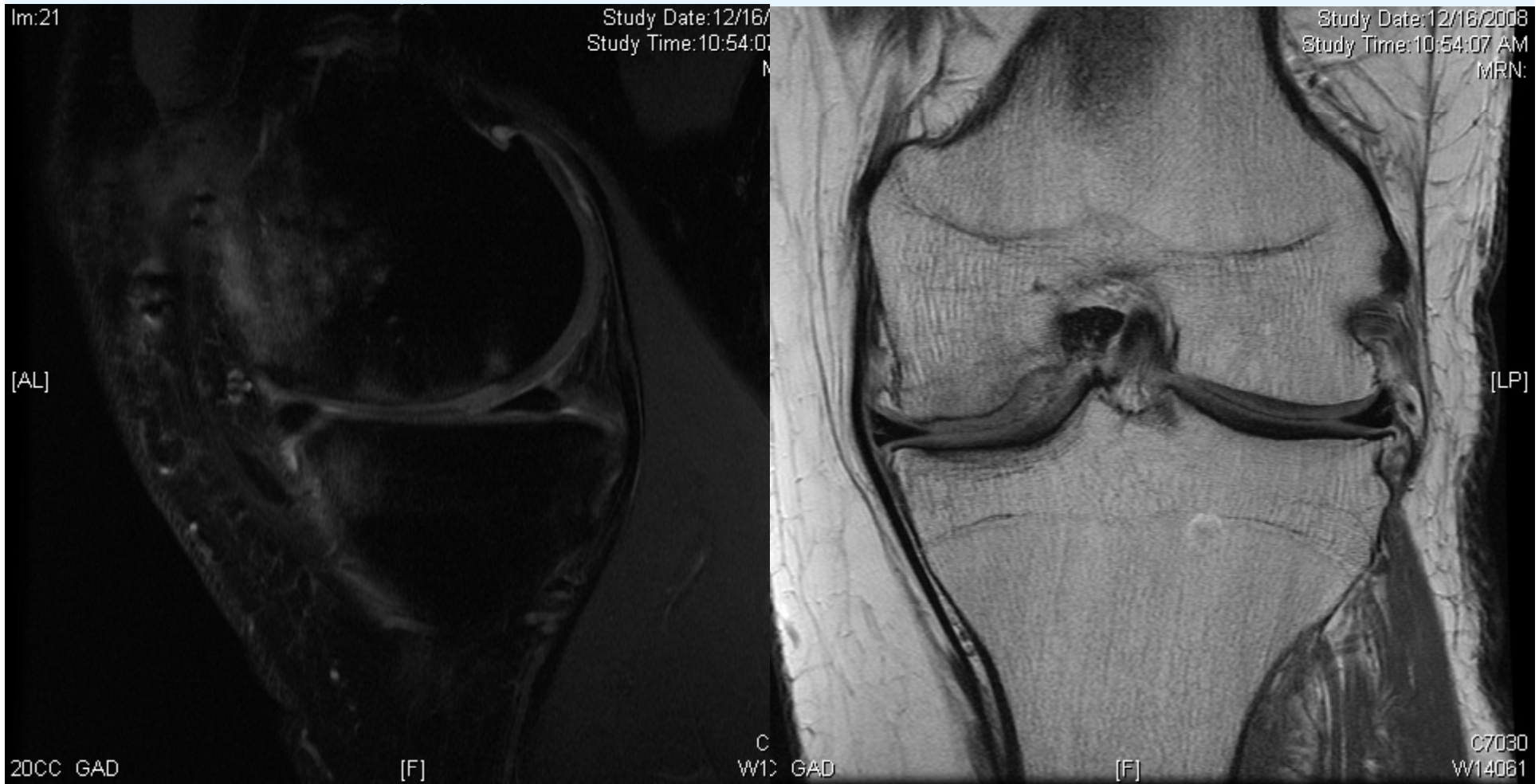




Cartilage Repair Center



MRI 8 mos.





Outcome

- Follow-up: 15 months
- Activity level: Unrestricted ADLs
Back to work at 7 mos. full-duty
- Symptoms: no pain, occasional mild swelling after climbing