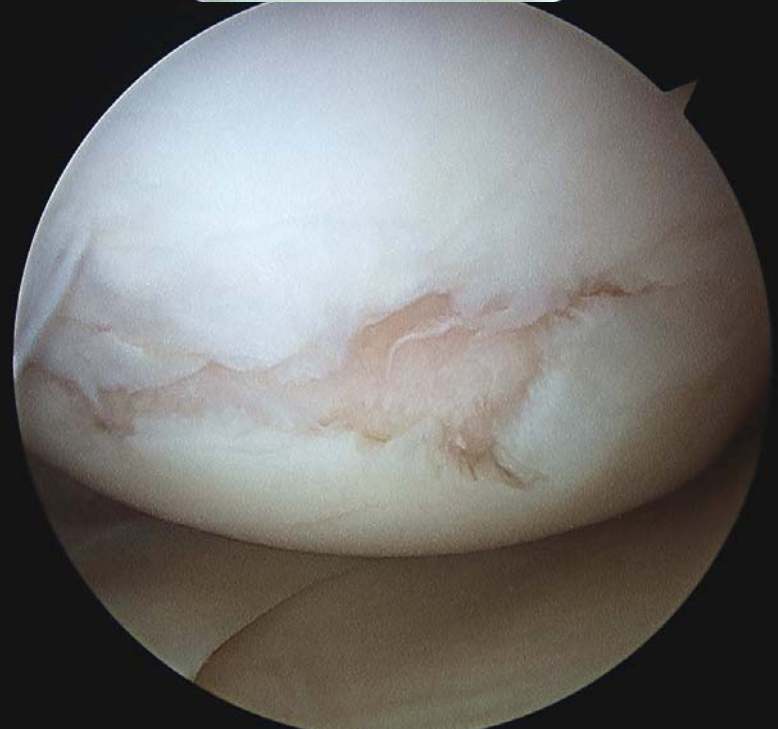
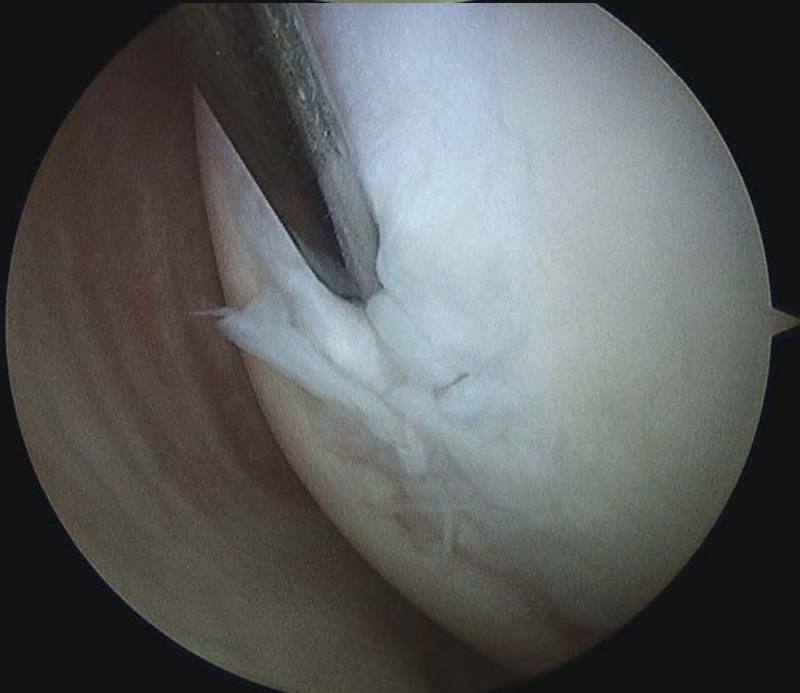
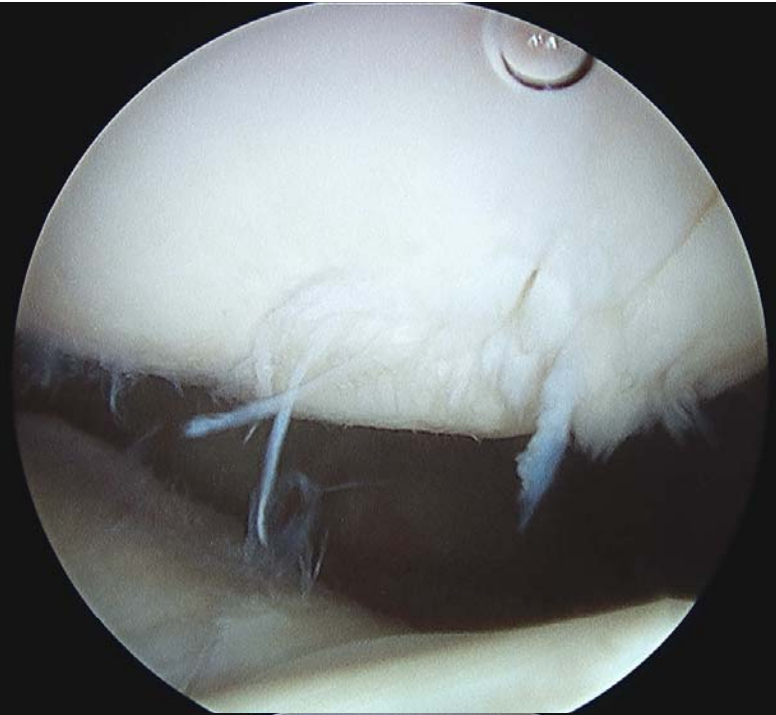
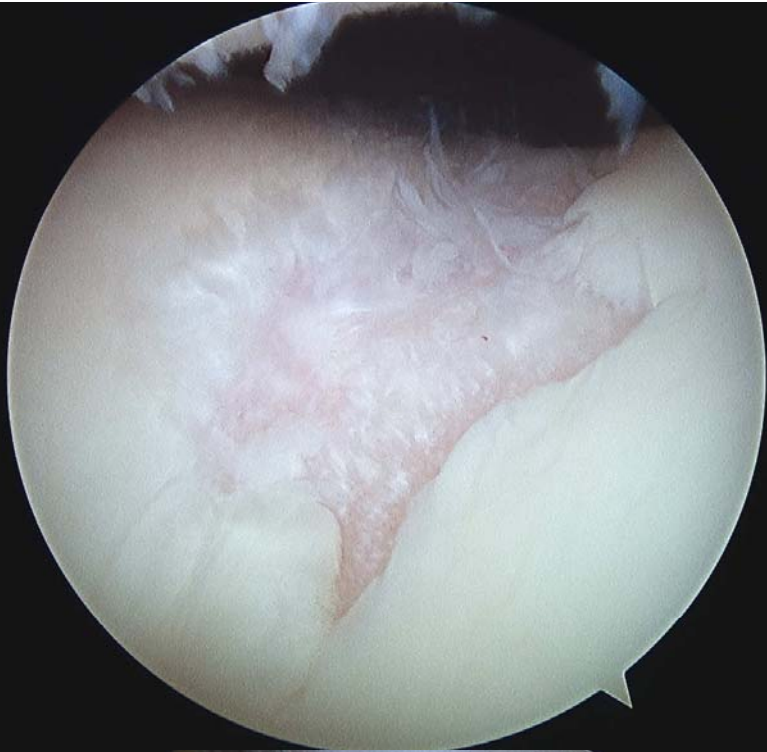
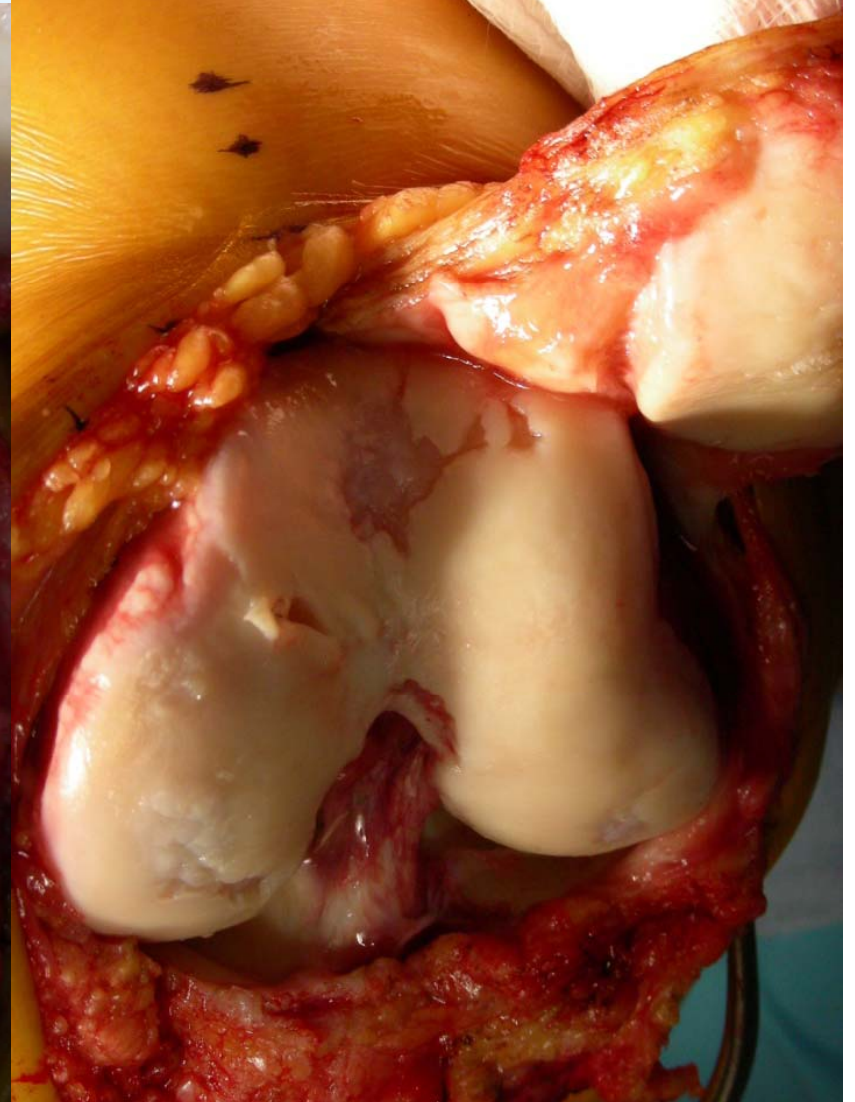
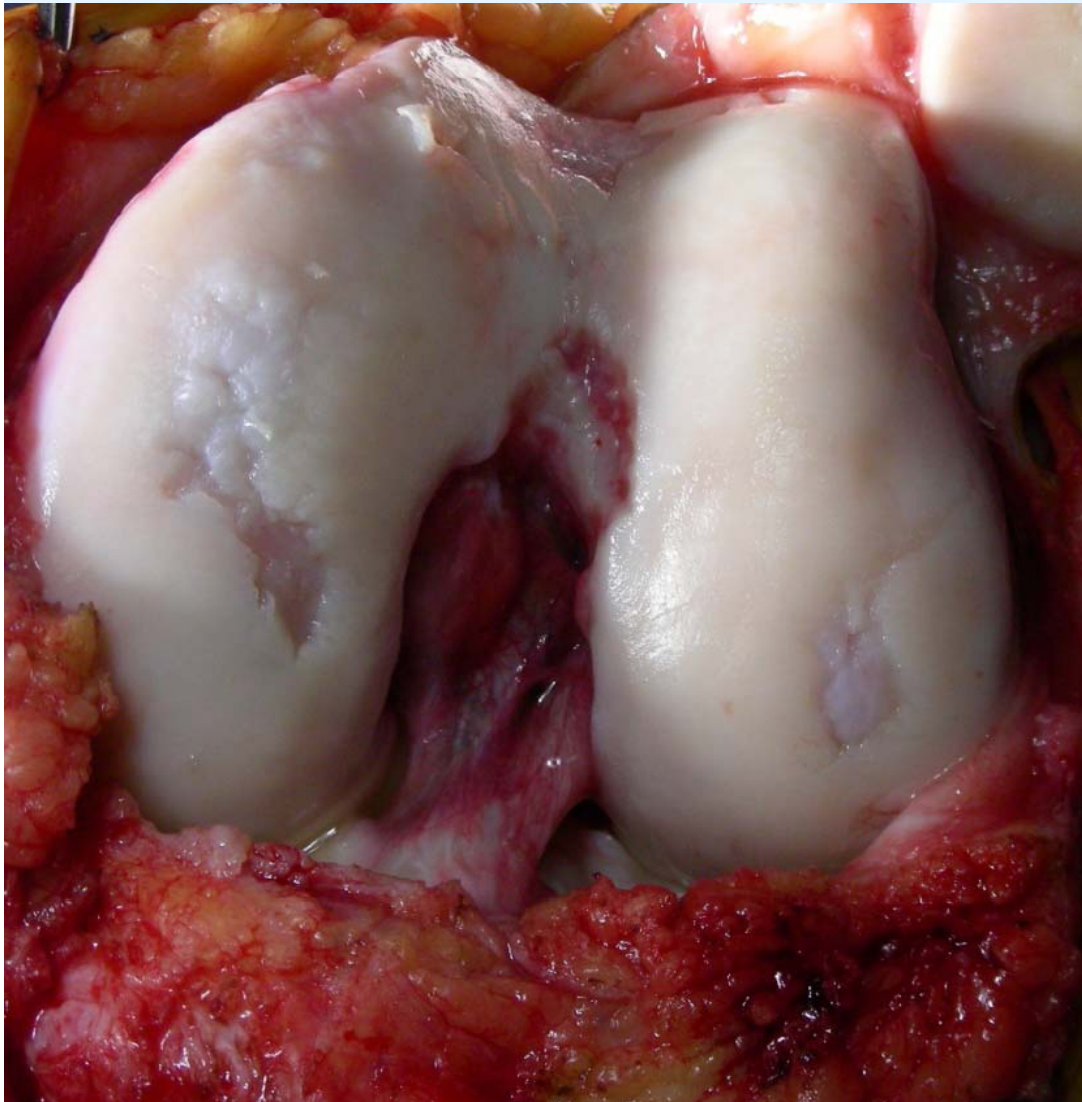
Patient Description

- Age: 32 yo
- Gender: Female
- Date of knee injury: Years ago
- Symptoms: Medial and anterior pain
- Previous surgery: Chondroplasty, microfracture, TruFit plug
- Co-morbidities:
 - Ligaments: stable
 - Alignment: neutral
 - Meniscus: normal
- Employment & activities of relevance:
Stay-at home mom
- Patient expectations:
Pain-free knee for ADLs



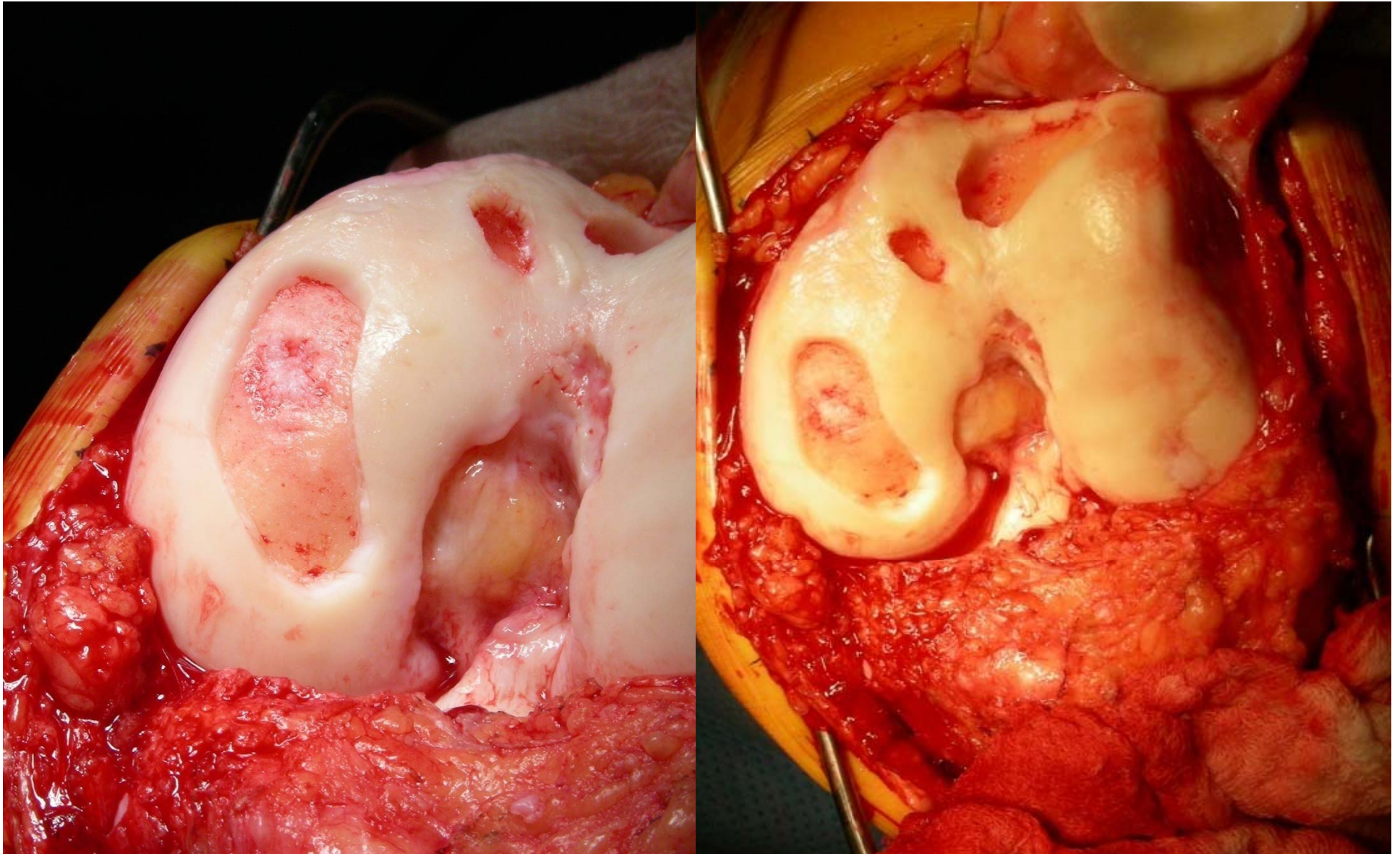


Cartilage Repair Center



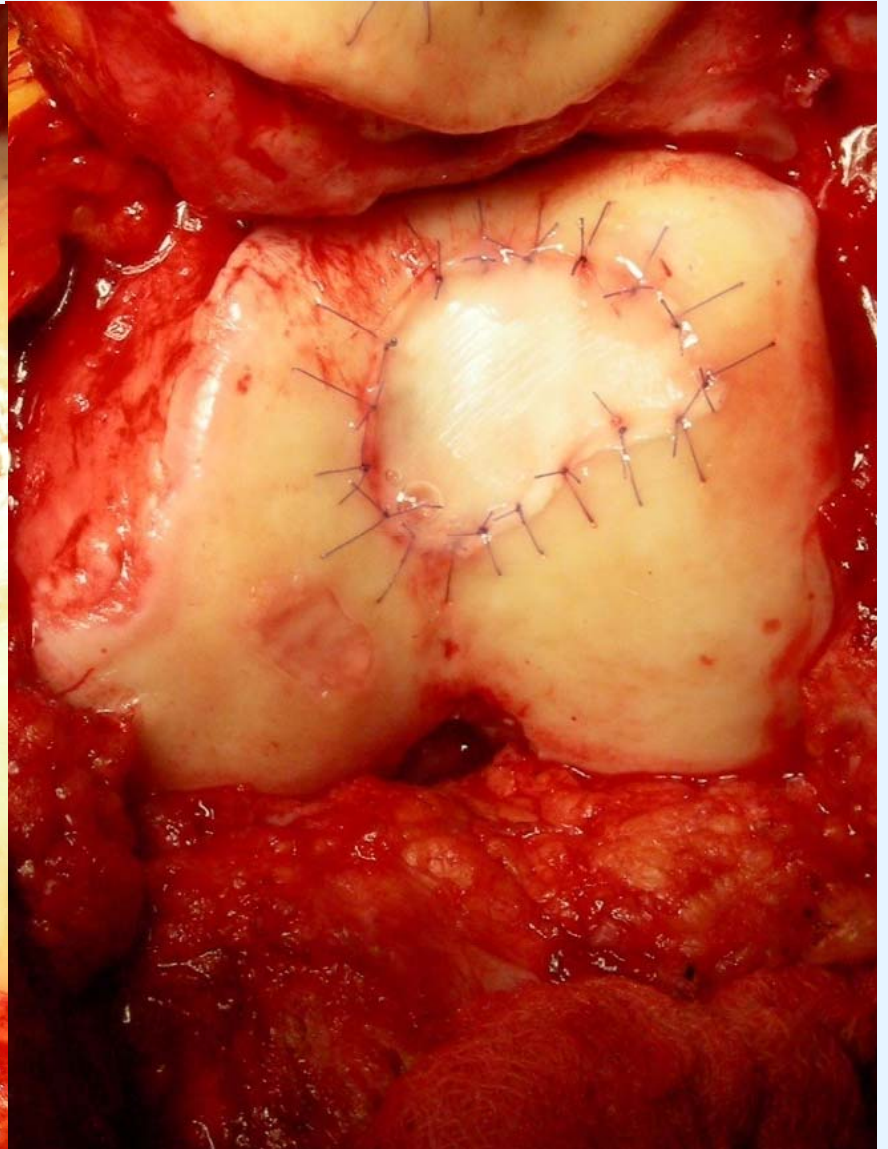
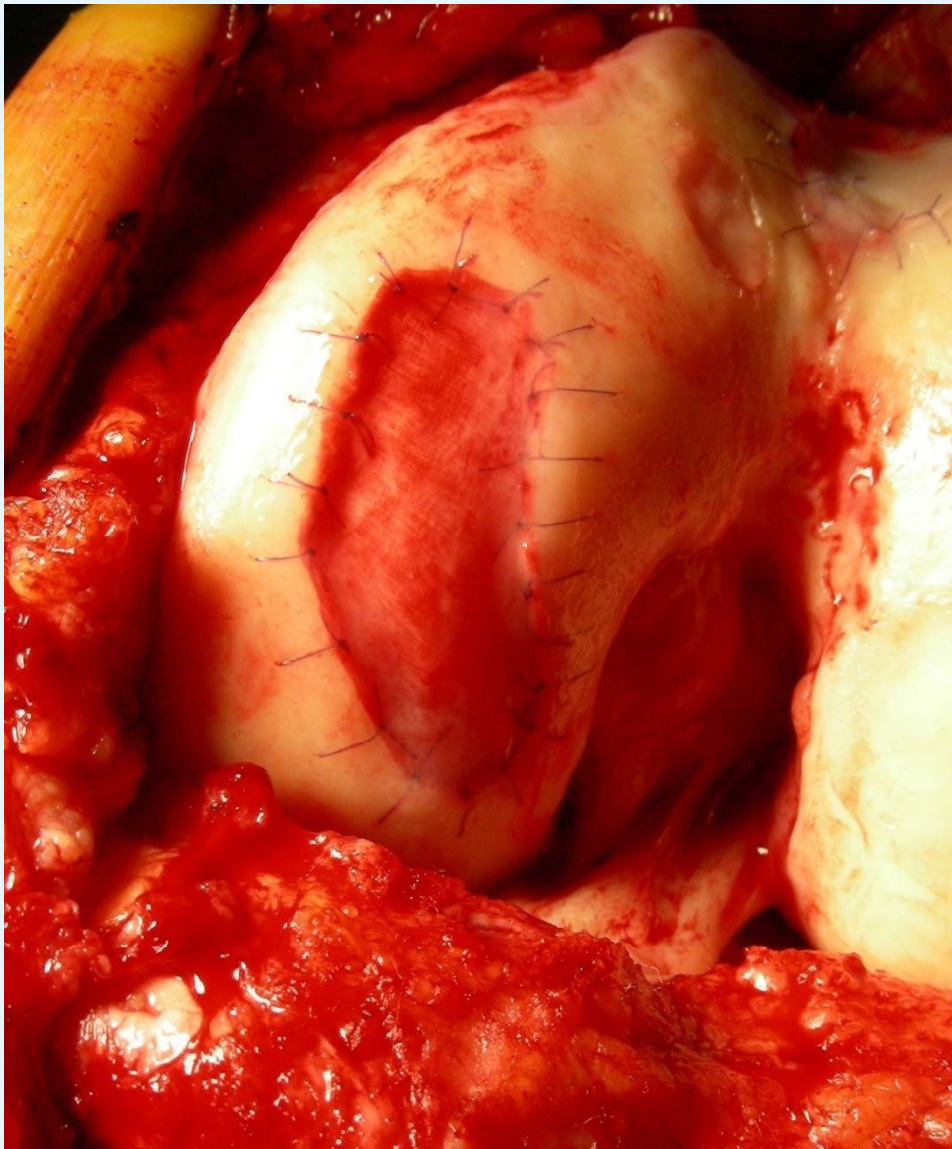


Cartilage Repair Center



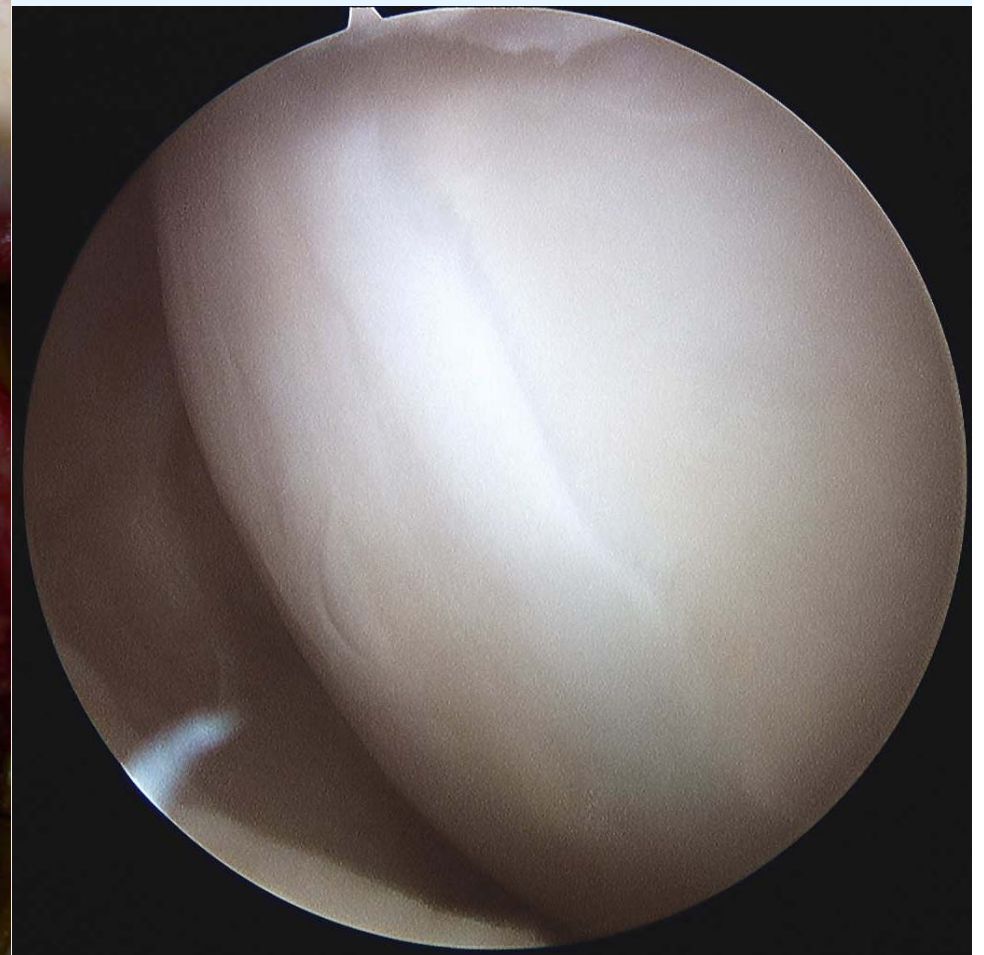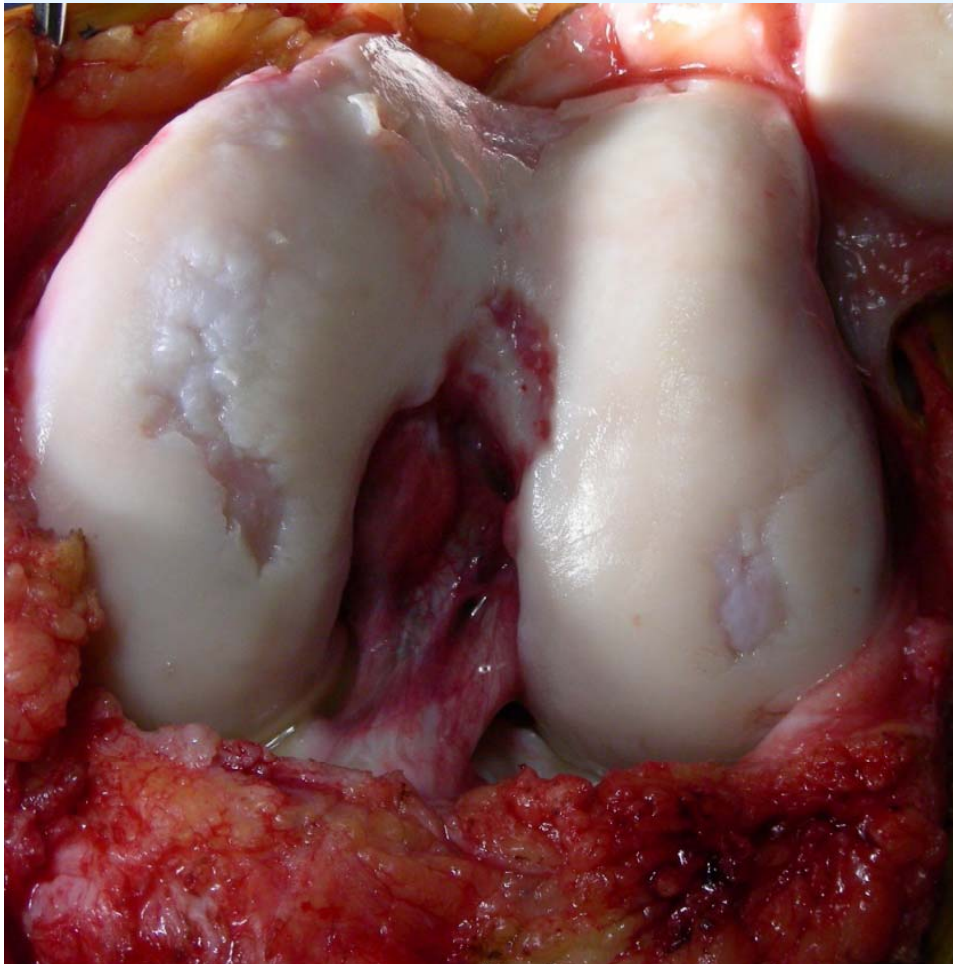


Cartilage Repair Center



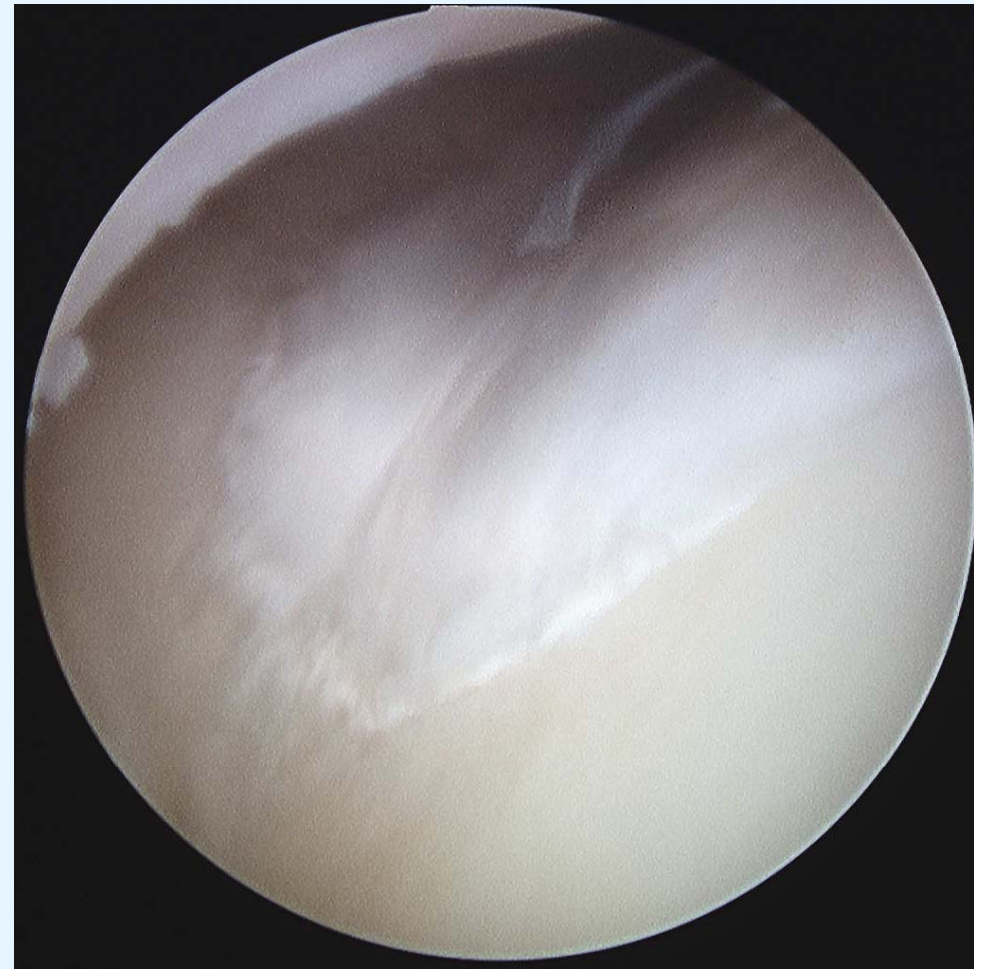
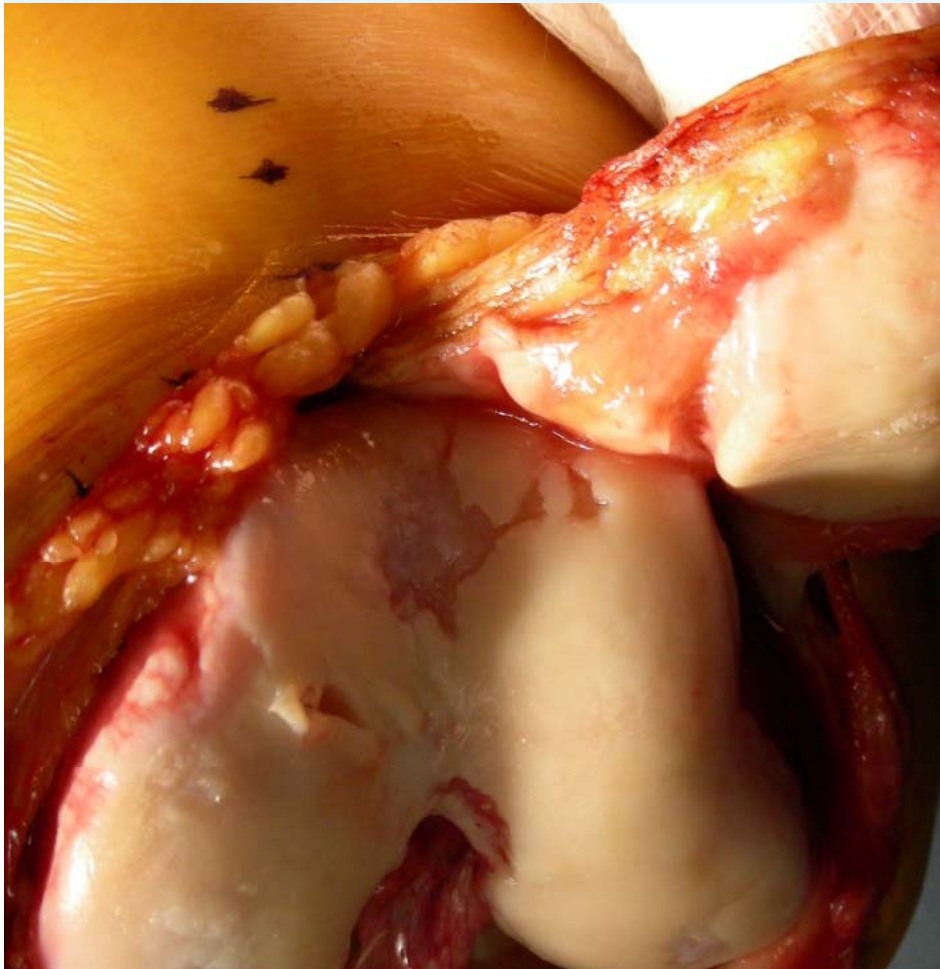


1 year 2nd look for meniscal tear



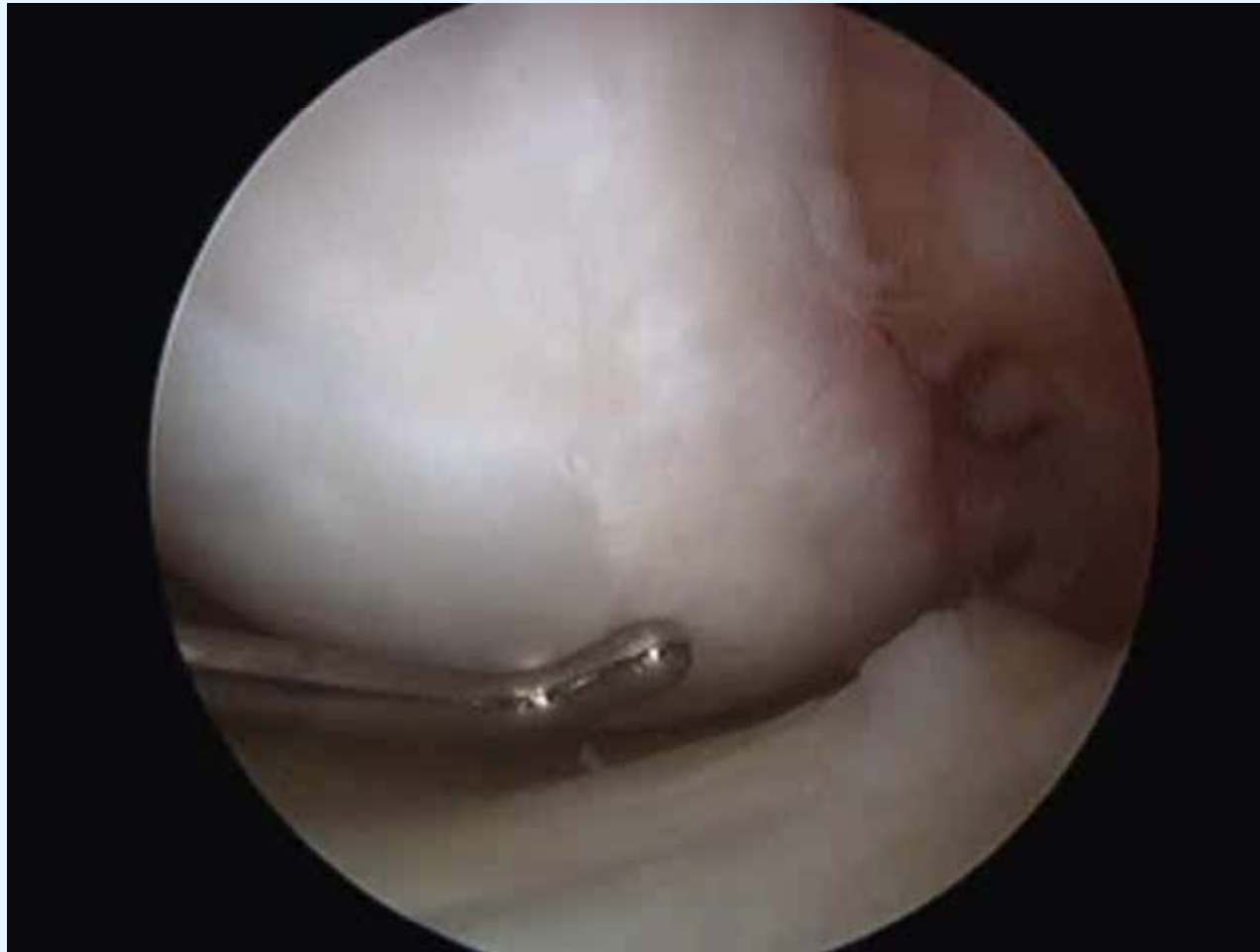

1 year 2nd look for meniscal tear





1 year 2nd look for meniscal tear





Cartilage Repair Center



15 months post-op





Outcome

- Follow-up: 24 months
- Activity level: Unrestricted activities, skiing, hiking
- Symptoms: no pain or swelling with ADLs
achiness after skiing, resolved by next day